Porcine Research

The embryonic development of the pig excretory system

[1]Elena Karalova, [1]Zara Semerjyan, [1]Astghik Manukyan, [2]Flora Iskandaryan, [2]Noela Panyan, [1]Zaven Karalyan, [3]Marina Tatoyan

[1] Laboratory of Cell Biology, Institute of Molecular Biology of NAS RA, Yerevan, Armenia; [2] Shushi University of Technology, Armenia; [3] Yerevan State Medical University after by M. Heratsi Department of Histology, Cytology and Embryology, Armenia.
Corresponding author: M. Tatoyan, marina.tatoyan@mail.ru

Abstract. It was shown, that on the 15th days after the conception (impregnation) in the pig embryos the prenephros have been revealed, consisted of several channel-like structures. They existed till the 3-rd week of embryogenesis, and then reduced, and by the 25th day of the pig embryonic development the primary kidneys came apparent, getting the maximal growth in the 25-35-days pig embryos. On the 45-th days of embryogenesis a big amount of the highly convoluted urinary tubules and also multiple Malpighean bodies have been revealed in them. Then mesonephros underwent involution, and on the 65-days embryos' slides the Malpighean glomeruli of the primary kidney are seen at the phases of degeneration and atrophy. Consequently, mesonephros functions during the first half of the pig intrauterine development, and then is followed by transformation into metanephros, which thereafter maintains as the final mature kidney. In the 75-days pig fetus the renal capsule is already seen, and underneath of which the cortical and medullar layers are clearly distinguished. The latter is formed by the collecting tubules, whereas the cortical layer is represented by the Malpighean bodies and the convoluted tubules. In mean, the Malpighean bodies' amount makes up 6-7/mm^2 of the section square area. Their structure is very similar to the structure of the Malpighean bodies of adult animal. The time dynamics of interchanges of pronephros, the primary and final kidneys and their relative sizes have been detected. It was revealed, that the maximal relative square area was for the final kidney in the 45-65-days embryos. Then, because of the pig fetus accelerated growth, forestalling the kidney growth, the relative square areas of kidneys becomes decreased. In result of the kidneys' weightings during the fetal period of development a significant absolute increase of the kidneys weight was revealed, although the relative weight and the growth intensity decrease during the fetal period of development, what probably, is conditioned by the kidneys earlier intensive growth as long ago as in the embryonic period of development.

Key Words: embryogenesis, urinary system, pronephros, mesonephros, metanephros, kidney.

Introduction. It is known, that the kidneys are the paired organs, which perform the homeostatic role in the organism's fluid content regulation and the metabolic wastes excretion (McMahon 2016; Grahammer et al 2013; Scott & Quaggin 2015). As the majority of organs in the organism, the kidney develops in result of the inductive interactions of the epithelial and mesenchimal tissues, which are formed just after the gastrulation process (Kuure et al 2000). The mammals' kidneys development differs from that of the majority of other organs by that it passes three consecutive phases. Each of them is characterized by formation of a pair of the more complex kidneys (Kanwar et al 2004). The earliest kidneys, called pronephros, develop just after gastrualtion and consist of several channel-like structures, and in the majority of vertebrates they have a rudimentary secretary function (Kanwar et al 2004; Desgrange & Cereghini 2015). The pronephros is being formed at the early stage of development, in 22 days after coitum in humans, and in 8 days in case of mice (Kuure et al 2000). In the mammals the main part of the pronephrotic channel degenerates, but the caudal part becomes a part of the excretory system and pertains to the Wolf's channel. Thereafter the pronephros is substituted by the primary kidney, which has an analogous to metanephros main

structure. These are the glomeruli with the well-developed vascular, proximal and distal tubules and the collecting ducts, being the Wolf's channel derivatives, have a great significance both for the meso-, and the metanephrogenesis. In humans and pigs the mesonephritic nephrons during embryogenesis are the functional excretory organs representing one of the biggest pig embryo's organs along with the liver and the heart. Hereafter, when the permanent kidney starts to function, the mesonephritic tubules regress, what leads to the mesonephros complete disappearance. Some of the key regulator molecules in mesonephrogenesis are similar to the permanent kidney and regulate not only the metanephritic, but also the mesonephritic differentiation (Sainio & Raatikainen-Ahokas 1999). In mammals, just metanephros is preserved as the final mature kidney and is characterized by widely-ramified system of collection and a big number of nephrons, which are the filtrating block of the kidney. Nephrogenesis is a complex process, as a result are formed nephrons, which are the main structural and functional units of the kidneys of vertebrates. This process starts with nearly the 5th week and ceases approximately by the 36th week of gestation in humans, during which about 1 mln nephrons per kidney are being formed, while their number is approximately 11,000 per kidney in mice (Hendry et al 2011; Short et al 2014). As it is known new nephrons are not formed after the birth (Schreuder et al 2011). Glomerulus at the nephron's proximal end filters the blood and is pervious for the filtrate into the tubular epithelium, which modifies it while getting the collecting tubules (Kuure et al 2000). This structure is important both for the metanephric kidney functioning, as it establishes an osmotic gradient between the cortical and medullar parts, leading to water extraction from the urine (Grahammer et al 2013). Structurally the mammals' metanephros consists of the internal medullar part, containing the collecting tubules and the long Henle's loops – the nephron segment, involved into the process of urine concentration (Kanwar et al 2004), and also the external medullar part, containing the short Henle's loops and the collecting ducts, as well as the cortical region with the all other parts of nephron.

Although the mammals' excretory system is quite well investigated, an issue of the time replacements of all three kidneys in pig embryogenesis and also the peculiarities of their structure, which depend of the embryonic development stages, are not studied enough, so this became a plot of our research interests.

Material and Method. In the present experiment 15 sows were used, which were covered when attaining the weight of 130-140 kg in the age of 11-12 months old. The first slaughter of the pregnant sows to study the pig embryos excretory system was performed in 15 days after covering, with encountering of the following slaughters on the 25, 45, 55, 65, 75 and the 90 days of pregnancy, as well as of the newborn piglet. Each time 3 sows were slaughtered and taken for the investigation. Euthanasia of the pigs was encountered according to the protocol Guide for the Care and Use of Laboratory Animals, AVMA Guidelines (Institutional Review Board/Independent Ethics Committee of the Institute of Molecular Biology of NAS, IRB00004079). The embryos were taken from the sows and their sizes were detected at all the stages of development under the magnifying glass with 5 times magnification, after what the embryos were fixed in the liquids of Zenker, Phlemming and Buen for the further histological investigations. The samples were embedded in paraffin with the following preparation of the serial histological slides of 8 microns of width. The preparations were treated with hematoxylin according to Weigert and Karachi followed by additional staining by eosin, by azan according to Heidenhain and by azan according to Mallory as well (Lillie 1965; Gray 1954).

Results and Discussion. It is known, that in mammals, and also in pigs, during embryogenesis three excretory organs are consecutively developed: the pre-kidney (prenephros), the primary kidney (mesonephros) and the permanent or the final kidney (metanephros). The urinary organs in the pig embryos are being developed just after the celome formation. At the pig embryos' primary differentiation phase, which lasts from the 11th till 15th days, the axial organs formation, as well as the pronephros development from peduncles of the primary mesodermal segments takes place. The prenephros is available in all the vertebrates at early stages of their embryonic development, and in

pigs it appears on the 2nd week of embryogenesis and functions up to the end of the 3rd week. Each prenephros consists of several tubules (protonephridia) (Figure 1 A, B), and the paired protonephritic duct then transforms into the Wolf's duct. Nearby the latter the papillary glomeruli are located, in which the process of liquid filtration takes place, during which liquid enters into the body cavity and thereafter into the tubule's lumen. Then in the pig embryos prenephros rapidly reduces (Figure 1 C, D) and transforms into the paired primary kidney.

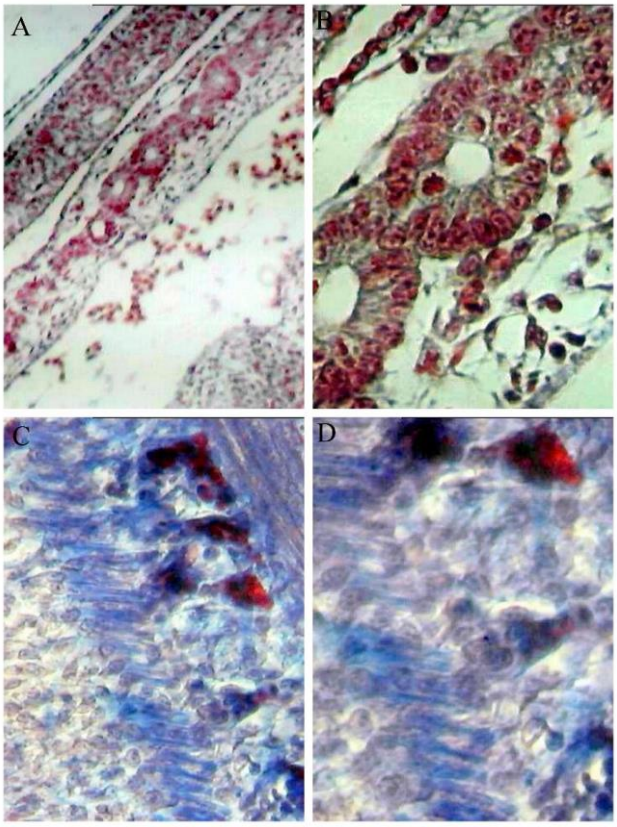

Figure 1. The pronephros of pig's embryo. Stained with azan by Mallory. A – the tubules of pronephrose are in 15-day pig's embryo, ocular 12.5, objective 4; B - ocular 12.5, objective 25; C - 25-day pig's embryo, reduction of the tubules, ocular 12.5, objective 25; D - ocular 12.5, objective 40.

By the 25th day of the pig embryonic development a formation of the body's abdominal cavity is fully competed, and the relatively big paired primary kidneys are already revealed. They consist of bulk of the interlacing tubules, rich in the blood vessels and the Malpighean bodies (Figure 2). This organ gets its maximal development in the 25-35-days pig embryos, representing one of the biggest organs along the liver and the heart. In literature the pigs primary kidney investigations mainly refer to the 40-42th days of the gestation period (Tiedemann 1985). Then mesonephros undergoes involution, and in the 55-65-day fetus is already represented by just not a big appendage on the internal wall of the definitive kidney. The primary kidney reduction process occurs in two phases in the same succession as its formation takes place: at first the cranial part reduces on the 35-45th days of embryogenesis, and then the caudal part - on the 45-65th days of that (Figure 3). In parallel with the destructive processes in the early embryo's mesonephros a disintegration of the renal bodies' cellular elements, as well as their migration into the gonads with completion of the differentiating cells in the latter take place. On the slides of the 65-days pig embryo the Malpighean glomeruli of the primary kidney at the phase of degeneration and atrophy are seen. The rudimentary residues of metanephros by the end of embryogenesis are not revealed.

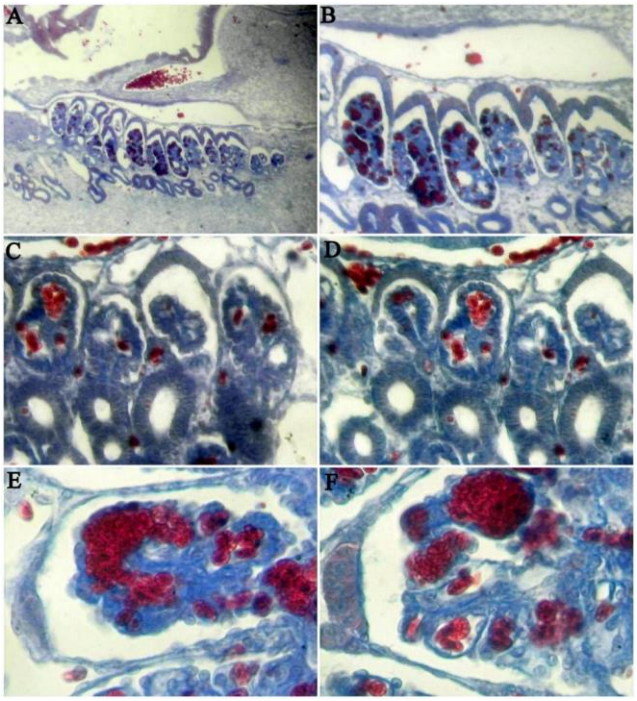

Figure 2. The mesonephros of 35-day pig's embryo. Malpighian corpuscles and tubules of the primary kidney. Stained with azan by Mallory. A – ocular 12, objective 4; B - ocular 12.5, objective 10; C -, D - ocular 12.5, objective 25; E -, F - ocular 12.5, objective 40.

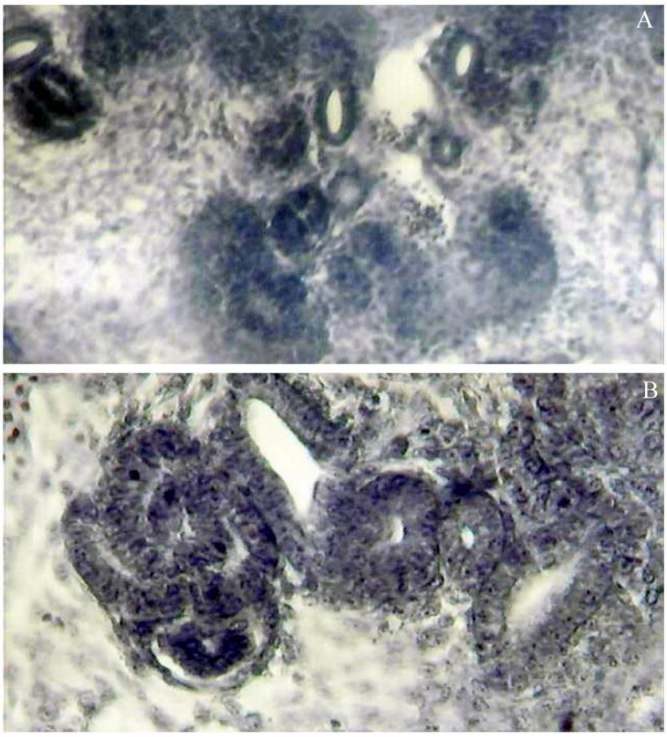

Figure 3. Malpighian bodies of the primary kidney 65 day pig's embryo. Degenerative and atrophic changes. A - stained by Heidenhain, ocular 12.5, objective 10; B - stained by Heidenhain ocular 12.5, objective 25.

Thus, the primary kidney in pigs functions during the first half of the intrauteral development (till 1.5 months after conception). That is pawned even when the prenephros exists, attaining its maximal development on the 35-45 days, and ceases in

the 65-75 days fetus. The final kidney or metanephros arises from the metanephrogenic tissue giving birth to nephrons formation, meanwhile from the ureter's primordium by means of intensive division of cells the epithelial integument of the ureter, pelvis of the kidney and the collecting ducts are formed. At the same time, along with that the mesenchime takes an active participation in the urinoexcretory ways formation, giving birth to all the rest wall tissues development. Metanephrons are preserved as the final mature kidney and are characterized by widely ramified system of collection and a big number of nephrons (about 11,000 in mice and 300,000-1 mln in humans). By its structure metanephros of mammals consists of the internal medullar region, containing the collecting tubules and the long Henle's loops, the nephronic segment, which is involved in the process of urine concentration, and the external medullar region, containing the short Henle's loops and collecting ducts, and also the cortical region, containing all the nephron's other parts. This gross structure is important for the nephron's functionality of the metanephrotic kidney, as it establishes the osmotic gradient between the cortex and the medullar layer, which results in extraction of water from the urine. As a filtrating block of the kidney a nephron serves, having a characteristic segmental organization. The glomerulus on the nephron's proximal end filters the blood and is pervious to the filtrate into the tubular epithelium, which modifies it till the urine delivery into the collecting channel for removal. The 45-days fetus kidney already has a characteristic bean-shaped form. From outside it is covered by the easily-detaching fibrotic tissue, rich in collagen fibers. But the kidney's histological structure is not specific yet: there is no division onto the cortical and medullar substances and the characteristic renal pyramids yet. On the transversal section a big number of the highly convoluted epithelial tubules, and namely, the urinary tubules in itself sense is observed (Figure 4 A, B).

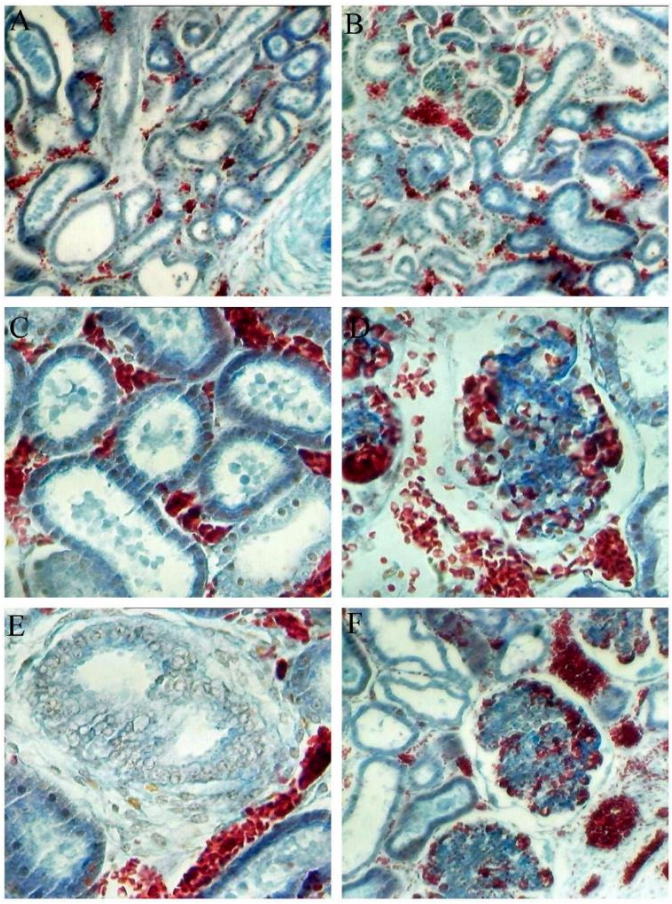

Figure 4. The metanephros of 45 day pig's embryo. Stained by Mallory. A -, B - medullar part formed by collecting tubules, ocular 12.5, objective 10; C - collecting tubules, ocular 12.5, objective 25; D -, E -, F - collecting tubules and Malpighian glomeruli, ocular 12.5, objective 25.

The urinoexcretory tubules, as it is known, containing the main mass of the medullar substance, are hardly represented here. Rather multiple Malpighean bodies are visible here: the closer to the kidney surface, the more they are. In mean, their amount is 6-7 Malpighean bodies/mm^2 of section square area. Their structure is highly similar to the structure of the Malpighean bodies of an adult animal. The outer wall of the capsule consists of the one-layer flat epithelium. The inner wall of the capsule tightly accreted with the vascular glomerulus. The vascular glomerulus consists of the arterial capillaries, lined up with epithelium, the borders of cells of which are too difficult to reveal. From outside the glomerular capillaries are covered with the reminding by their shape and way of staining connective tissue cells, which also covers the capillaries of other organs (Figure 4 E, F, G).

On the slides a great number of the blood vessels and capillaries become too apparent, which fill almost the whole free space between the tubules, and especially clearly highlighted due-to the sharply stained erythrocytes. As per character of the forming cells in the renal tubules the main parts, the epithelial cells of which have a characteristic turbid hue of cytoplasm are clearly distinguished. By means of our applying methods of staining (azan, hematoxylin-eosin) their boards cannot be distinguished, nevertheless in azan staining it is possible to note the specific cuticular edge, stained in blue color (Figure 5).

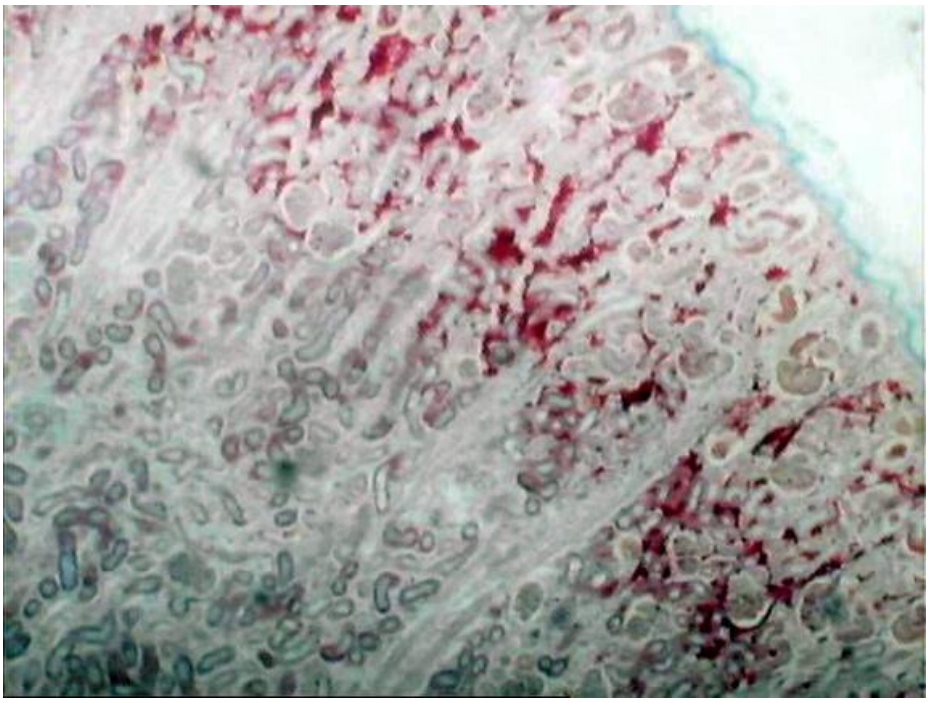

Figure 5. The metanephros of 75 day fetus of a pig. A capsule of the kidney is visible. Under the capsule a cortical and medullar parts are clearly visible. Stained with azan by Mallory, ocular 12.5, objective 4.

Epithelial cells of the other parts of the much lower located renal tubules have protoplasm stained in light-blue color and rather clear borders. From the above-described pattern we can conclude that the early fetus kidney is already well-developed organ, and probably, one of the most developed ones. Hereafter, during the fetal period of development in main just the Malpighean bodies' number increase takes place, amount of which gets 25/mm^2 of section square area in the 65-days fetus. Correspondingly to that the number of tubules also increases (Figure 6). An important distinguishing feature of the late fetus kidney is a presence of the medullar layer (Figure 7), formed by the collecting tubules.

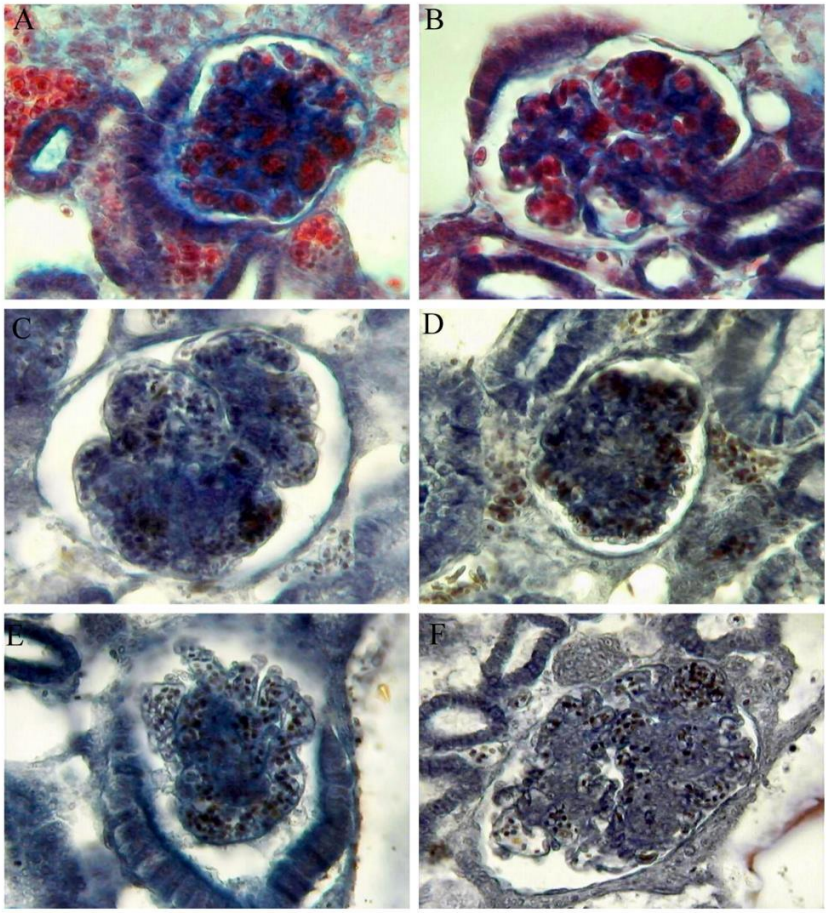

Figure 6. The metanephros of 65 day pig's fetus. A-, B- Malpighian glomeruli. Stained with azan by Mallory, ocular 12.5, objective 25; C-, D-, E-, F- collecting tubules and Malpighian glomeruli. Stained stained with azan by Heidenhain, ocular 12.5, objective 25.

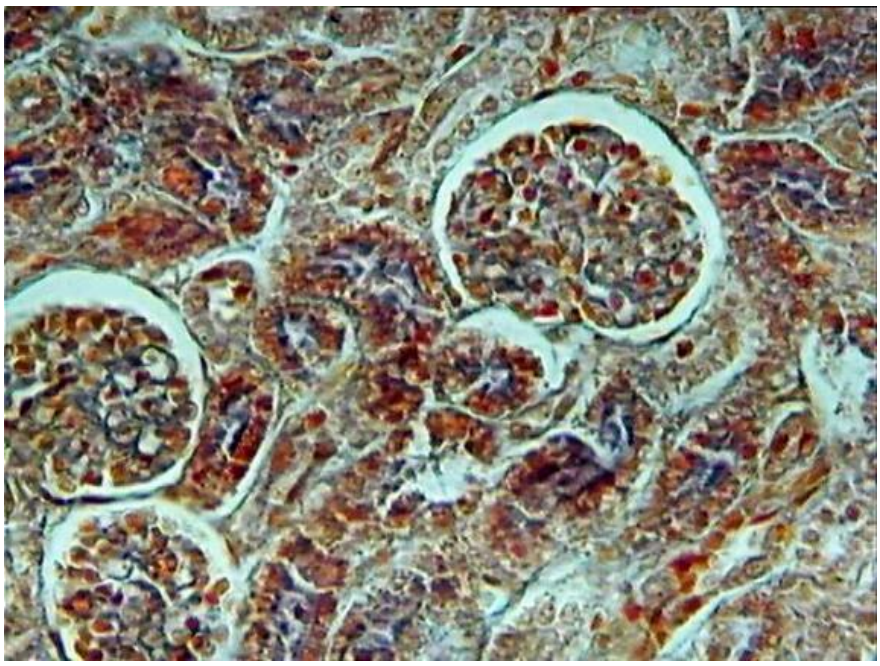

Figure 7. The final kidney of a newborn pig. Malpighian glomeruli and urinary tubules are visible. Stained with azan by Heidenhain, ocular 12.5, objective 25.

The medullar layer is extremely rich in the blood vessels and capillaries. From outside the kidneys of newborn piglets and even the month-aged piglets have clearly expressed "lobular" structure owing to the continuing even at this age the renal pyramids' growth, which obtain the characteristic for them structure already in a newborn piglet (Figure 8).

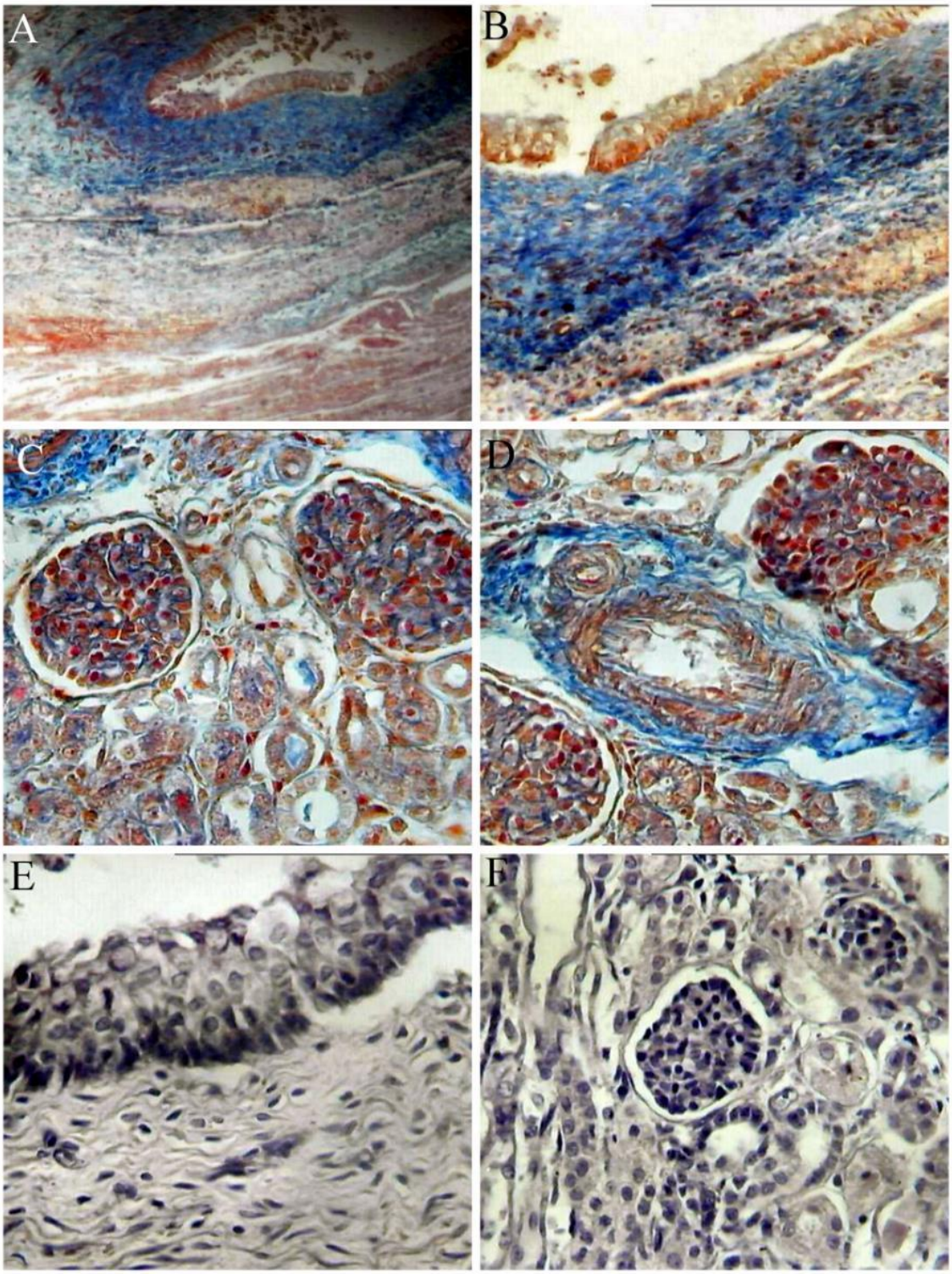

Figure 8. The final kidney of a newborn pig. A-, B- capsule of the kidney. Stained with azan by Mallory, ocular 12.5, objective 4; B- ocular 12.5, objective 10; C-, D- collecting tubules and Malpighian glomeruli, ocular 12.5, objective 25; E- capsule of the kidney; F- collecting tubules and Malpighian glomeruli. Staining with hematoxylin-eosin, ocular 12.5, objective 25.

It should be noted, that during the process of development the renal tubules differentiation goes in the direction from the closest to the renal pelvis parts to the superficial layers. In the upmost superficial layers even some period after the birth a low-differentiated cellular material remains, from which new renal tubules continue differentiate. According to Carlson (1983), the cortical matter is represented by the Malpighean bodies, the convoluted tubules, as well as insignificant part of the renal's medullar part is represented by the direct tubules of the Henle's loops. The major part of the medullar substance, in particular, the collecting ducts and the excretory ducts system develop from the metanephric diverticulum of the Wolf's channel. The cortical and medullar substances formation continues during the whole period of the embryonic development, and even during the first week after the birth. In the 75-days pig embryo the mature final kidney formation is apparent, with the characteristic division of the cortical and medullar substances. From the above-described we may conclude that the fetal kidney is a well-developed organ, and probably, one of the most developed ones. Hereafter, during the fetal period of development in main just the Malpighean bodies' number increase takes place, amount of which gets 25/mm^2 of section square area in the 65-days fetus. Correspondingly to that the number of tubules also increases.

In the Figure 9 the replacement dynamics of the pronephros, the primary and the final kidneys in the pig embryogenesis is represented schematically. Together with this the relative square areas of kidneys are also represented on the graph.

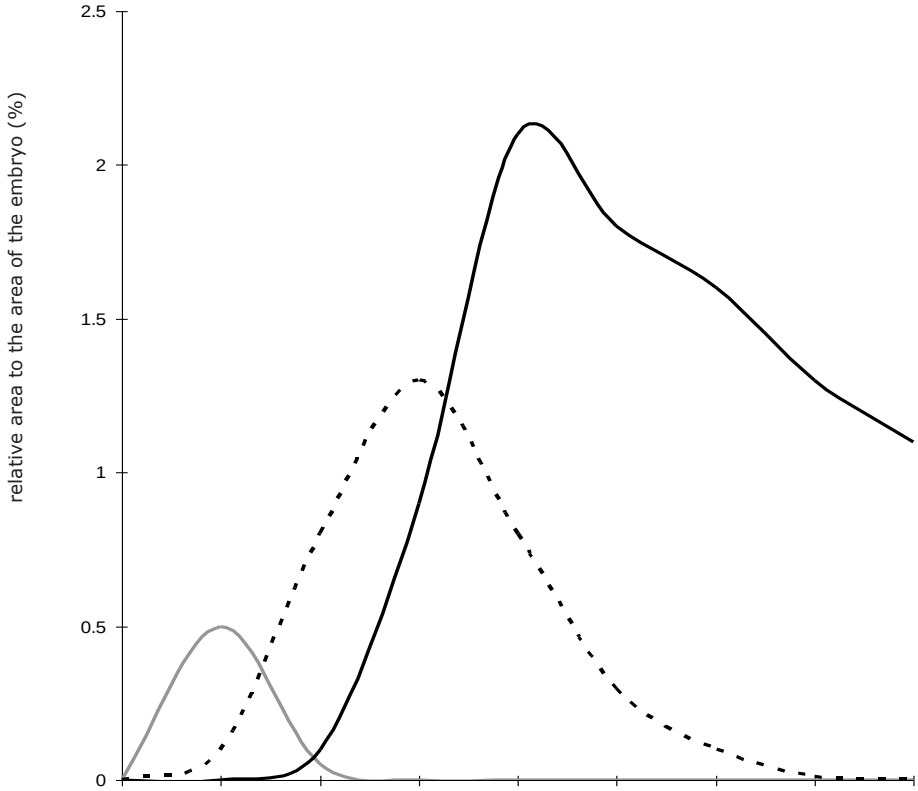

Figure 9. Temporal dynamics of renal replacement and their relative size in pig embryogenesis.

The relative square areas values were calculated on the embryonic slides at different periods of embryogenesis. Each time not less than 4 slides were explored taken from each embryo. For each period not less than 3 embryos were used in experiment. As it can be seen in Figure 9, the most relative square area was for the final kidney on the 45-65-days embryo. Hereafter, because of the pig fetus accelerated growth, which forestalls the kidneys growth, the kidneys relative square areas decrease occurs.

The kidneys weighing data (Figure 10) testify about the significant absolute increase of the kidneys weight during the fetal period of development. As for the relative weight and the growth intensity, these both indices decrease during the fetal period of development. This, probably, is also conditioned by the kidneys' earlier intensive growth as long ago as in the embryonic period of development.

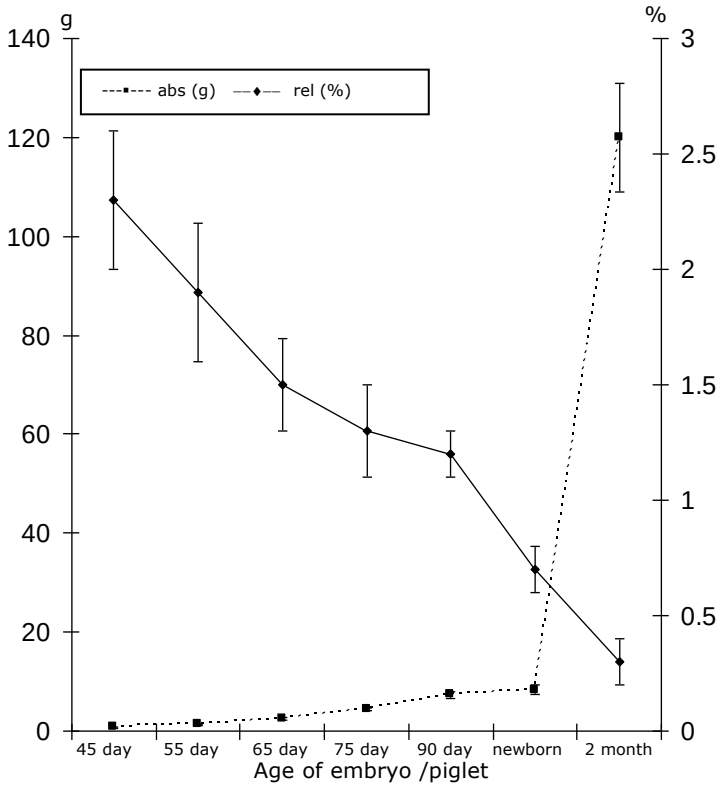

Figure 10. Dynamics of absolute and relative weight of pig's fetus and intensity of its growth.

Conclusions. Thus, the terms of organogenesis of all three types of kidneys are clarified. Thus, the pig pronephron was revealed on the 15-days after the conception (fertilization) and was reduced by the third week of embryogenesis. That was replaced by mesonephros, which attained its maximal development by the 35-45 days, and ceased in the fetus by the 65-75 days. On the 45th days of embryogenesis in mesonephros a big amount of the highly convoluted urinary tubules and also rather multiple Malpighean bodies were revealed. Then mesonephros underwent involution, and on the 65-days embryos' slides the Malpighean glomeruli of the primary kidney at the phases of degeneration and atrophy are seen. Already on the 45th days of the fetus embryogenesis the final kidney or the metanephros was revealed, which is of characteristic bean-like shape, and in the 75-days pig embryo the final kidney formation is observed with the characteristic division onto the cortical and medullar substances. From the above-described pattern we may conclude that the fetal kidney is a well-developed organ. Hereafter, in main, just the Malpighean bodies' number increases, getting 25/mm^2 of section square area in the newborn piglet, and correspondingly to that the number of tubules also increases.

Investigation of the replacement time dynamics of prenephros, the primary and the final kidneys and of their relative sizes revealed, that their maximal relative square area was for the final kidney in the 45-65-days embryos. Then, the kidneys' relative square areas decrease occurs due-to the pig fetus accelerated growth, which forestalls the kidneys growth. The kidneys' weighing data testify about the significant absolute increase of the kidneys weight during the fetal period of development, but herein the relative weight and the growth intensity during the fetal period of development decrease,

what much likely is conditioned by the kidneys earlier intensive growth as long ago as in the embryonic period of development.

References

Carlson B. M., 1983 Patten's foundations of embryology. McGraw-Hill Book Company.

Desgrange A., Cereghini S., 2015 Nephron patterning: Lessons from Xenopus, zebrafish, and mouse studies. Cells 4(3):483-499.

Grahammer F., Schell C., Huber T. B., 2013 The podocyte slit diaphragm—from a thin grey line to a complex signalling hub. Nat Revi Nephrol 9(10):587–598.

Gray P., 1954 The Microtomist's formulary and guide. Robert E. Krieger Publishing Co.

Hendry C., Rumballe B., Moritz K., Little M. H., 2011 Defining and redefining the nephron progenitor population. Pediatr Nephrol 26(9):1395–1406.

Kanwar Y. S., Wada J., Lin S., Danesh F. R., Chugh S. S., Yang Q., Banerjee T., Lomasney J. W., 2004 Update of extracellular matrix, its receptors, and cell adhesion molecules in mammalian nephrogenesis. Am J Physiol Renal Physiol 286(2):202–215.

Kuure S., Vuolteenaho R., Vainio S., 2000 Kidney morphogenesis: cellular and molecular regulation. Mech Dev 92(1):31-45.

Lillie R. D., 1965 Histopathologic technic and practical histochemistry. McGraw-Hill, New York.

McMahon A. P., 2016 Development of the mammalian kidney. Curr Top Dev Biol 117:31–64.

Sainio K., Raatikainen-Ahokas A., 1999 Mesonephric kidney – a stem cell factory? Int J Dev Biol 43(5):435-439.

Schreuder M. F., Bueters R. R., Huigen M. C., Russel F. G. M, Masereeuw R., van den Heuvel L. P., 2011 Effect of drugs on renal development. Clin J Am Soc Nephrol 6:212–217.

Scott R. P., Quaggin S. E., 2015 The cell biology of renal filtration. J Cell Biol 209(2):199–210.

Short K. M., Combes A. N., Lefevre J., Ju A. L., Georgas K. M., Lamberton T., Cairncross O., Rumballe B. A., McMahon A. P., Hamilton N. A., Smyth I. M., Little M. H., 2014 Global quantification of tissue dynamics in the developing mouse kidney. Dev Cell 29(2):188–202.

Tiedmann K., 1985 The pig mesonephros. III. Distal tubule, collecting tubule, and Wolffian duct: SEM- and TEM-studies. Anat Embryol (Berl) 172(1):123-32.

Received: 20 June 2018. Accepted: 27 July 2018. Published online: 06 August 2018.

Authors:

Elena Karalova, Institute of Molecular Biology of NAS, Laboratory of Cell Biology, Armenia, Yerevan, 0014, Hasratyan St. 7, e-mail: karalovae@gmail.com

Zara Semergyan, Institute of Molecular Biology of NAS RA, Laboratory of Cell Biology, Armenia, Yerevan, 0014, Hasratyan St. 7, e-mail: zarasem@gmail.com

Astghik Manukyan, Institute of Molecular Biology of NAS RA, Laboratory of Cell Biology, Armenia, Yerevan, 0014, Hasratyan St. 7, e-mail: astxik-manukyan@mail.ru

Flora Iskandaryan, Shushi University of Technology, Armenia, Ashot Bekor str. 4, Shushi, e-mail: flora.iskandaryan@yandex.com

Noela Panyan, Shushi University of Technology, Armenia, Ashot Bekor str. 4, Shushi, e-mail: z_karalyan@mb.sci.am

Zaven Karalyan, Institute of Molecular Biology of NAS RA, Laboratory of Cell Biology, Armenia, Yerevan, 0014, Hasratyan St. 7, e-mail: zkaralyan@yahoo.com

Marina Tatoyan, Yerevan State Medical University, M. Heratsi Department of Histology, Cytology and Embryology, Armenia, Yerevan, 0025, Koryun St. 2, e-mail: marina.tatoyan@mail.ru

How to cite this article:

Karalova E., Semergyan Z., Manukyan A., Iskandaryan F., Panyan N., Karalyan Z., Tatoyan M., 2018 The embryonic development of the pig excretory system. Porc Res 8(1):1-11.